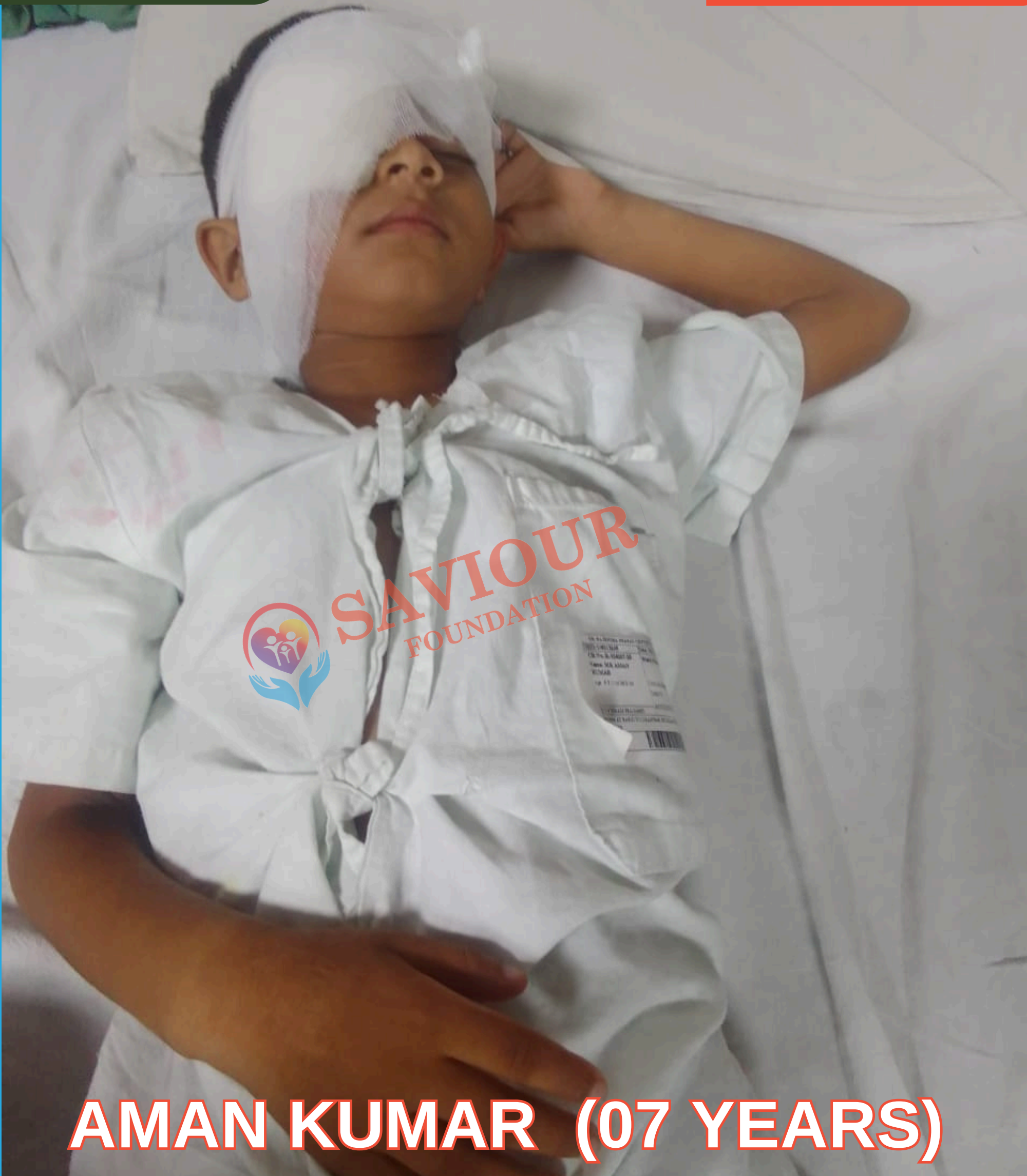

TAX BENEFITS

URGENT SUPPORT



AMAN KUMAR (07 YEARS)

UHID - 108313265

Retinoblastoma Eye Cancer

www.savioursfoundation.org



JHID: 108313285

ABHA:

Dept No: 20250050054757

संख्या / Queue 22

कमरा / Room: 43

Unit-V

RPC OPD

AMAN KUMAR

Dr M S Bajaj

S/O VIKRAM PRAJAPATI

7Y 12D / N.E. Eye

AT BARJOLIC DHANWAR PS DHANWAR

PIN 825412 JAMMU AND KASHMIR, INDIA

General Rs. 0

Follow Up Patient

TUE, FRI

मंगल, बुध



Registration time:

24/08/2028 09:55:47 AM

पता

Address

निदान

DIAGNOSIS

उपचार Treatment

Adv →

(wound healthy)

Tarsorrhaphy (+)



SAVIOUR FOUNDATION

continue

(RE)

Eld / Elo

Vigamox 3T/D

ocupol TDS

⇒ Review & reports (HPE)
(Tue (Fri))

इस कार्ड को सुरक्षित रखें तथा अस्पताल में दिखाने के समय हर वक्त साथ लायें।

Kindly keep this Card safely and bring it on your follow-up visits.

धूम्रपान निषेध
No Smoking

2. कूड़ा कर्कट केवल कूड़ेदान में ही डालें

2. Use Dustbin

3. थूकिये नहीं

3. No Spitting

(E7)

(32)

27 JUN 2025

HPE s/o Poorly differentiated RB c necrosis & calcificati
Massive choroidal invasion (+)
Optic N. including cut end is free of tumor.

cls/B Dr. Rashtra

Date for GUA

Pls. accmo date in Dharamshala

Adv 6 cycles of chemo prophylaxis

Cilv/0 massive choroidal invasion
Risk of metastasis.

IRCH (med-onco)

Ref to Dr Sameer Bakshi
Dekh
MON/Thurs day

EVA-ON
15/09/2025
57 5th floor
8:30 AM

Dr. ASHIMA SACHDEVA
Senior Resident
Dr. R.P. Centre for Ophthalmic Sciences
New Delhi, 20

नेत्र ईश्वरीय सर्वश्रेष्ठ उपहार है जिनका मनुष्य जीवन में दान करना परमश्रेष्ठ है।
इनकी पूर्ण रक्षा कीजिए ताकि ये आपकी रक्षा कर सकें।

Eyes are God's most precious gift to man kind and eye donation is the most noble deed.
Take full care of them so that they can take care of you.

R. P. Centre (Eye Centre)

UHID: 108313265

Dept. No. 20250050054757

Clinic. No.: 2025/RB/128

AMAN KUMAR

S/O: VIKRAM PRAJAPATI

Date: 15/05/2025

General
२०

Retinoblastoma-Dr. SR/JR

RB -V- R.142 B

Unit-V

Room No.: 142 B

अनुभाग व दिन
Section and Day V
मंगलवार व शुक्रवार
Tuesday & Friday

कमरा नंबर
Cabin No.

Address: AT BARJO PO DHANWAR PS DHANWAR PIN 825412, JAMMU AND KASHMIR, INDIA

पू. ए. ए. जा. २०२५



...एस. बजाज का एकक

UHID No. 108313265

Prof. M.S. Bajaj's Unit

रोगी का नाम Name of the Patient	पुत्र/पुत्री/पत्नी S/D/W	लिंग Sex	आयु Age	पता Address
Amman Kumar		M	64	

दिनांक DATE	निदान DIAGNOSIS	उपचार Treatment

② Gsp E Ab / Diffuse infiltr
Ab

13/5/2025

CE MRI 10/4/24
s/o Diffuse
infiltration Ab



ROP T
Epithelial edema
Diffuse infiltration
of retina
with vitreous
seeds

CE MRI: orbit & Brain
to s/o extraocular

Abhera Wed/Fri

PRE
Flu In RB Clinic
142B (Thursday)
15/05/25

कृपया इस कार्ड को सुरक्षित रखें तथा अस्पताल में दिखाने के समय हर वक्त साथ लायें।

Kindly keep this Card safely and bring it on your follow-up visits.

- धूम्रपान निषेध 1. No Smoking
- कूड़ा कर्कट केवल कूड़ेदान में ही डालें 2. Use Dustbin
- थूकिये नहीं 3. No Spitting

ब. रो. वि. कार्ड O.P.D. Card




नेत्र अमृत उपचार के
सा ज्ञान ही दे सकते हैं

अनुभाग व दिन
Section and Day V
मंगलवार व शुक्रवार
Tuesday & Friday

कमरा नंबर
Cabin No.

151-B

डा. राजेन्द्र प्रसाद नेत्र विज्ञान केन्द्र
अ. भा. आयु. सं., नई दिल्ली-110029

Dr. Rajendra Prasad Centre for Ophthalmic Sciences
A.I.I.M.S., New Delhi-110029

यू.एच.आई.डी. संख्या

आचार्य एम.एस. बजाज का एकक

UHID No. 108313265

Prof. M.S. Bajaj's Unit

रोगी का नाम Name of the Patient	पुत्र/पुत्री/पत्नी S/D/W	लिंग Sex	आयु Age	पता Address
Aman Kumar				

दिनांक DATE	निदान DIAGNOSIS
----------------	--------------------

16/5/25

उपचार Treatment

16/5/25
 16/5/25 SR Mohan LPRC Unit 5
 RE intraocular mass 2x2mm RD
 Coats WNL. Type
 ON normal. No ON enhancement
 No scleral breach involvement.
 No signs of extraocular spread.

कृपया इस कार्ड को सुरक्षित रखें तथा अस्पताल में दिखाने के समय हर वक्त साथ लायें।

Kindly keep this Card safely and bring it on your follow-up visits.

- धूम्रपान निषेध
- कूड़ा कर्कट केवल कूड़ेदान में ही डालें
- थूकिये नहीं

1. No Smoking

2. Use Dustbin

3. No Spitting

SUMMARY
Admission Notes

Report on admission by Junior Resident based on history, physical findings and investigations indicating line of the treatment and differential diagnosis

Retinoblastoma

Stage 1

Group

- A : RB < 3mm size, away from fovea
- B : > 3mm size
- C : localised in vitreous
- D : Diffuse vitreous involvement
- E : tumor size > 1/2 of eyeball

Chemo : VEC flb
laser flb eye
- Enucleation.

Stage 2

Optic nerve involved - Enucleation + post op chemo + Radio T.

Stage 3

Exenteration (taking out eyeball, esm, fat, eyelid, lacrimal gland, bones)
do Leukocoria :: 5 months back
at (5 1/2 yrs) of age

Stage 4

Metastasis
Palliative symptomatic Tx



* No family H/O.

* ⊕ Ectropion uvulae
Dilated pupil
Diffuse Corneal Edema
Leukocoria ⊕

Date

Signature

Review notes by the Senior Resident

NO 81

VAC

R/E GROUP E Retinoblastoma

NCT

L/E fellow Eye
upfront

Date

plan: R/E Enucleation ↓ GFA
+ EVA

Signature SRV

2

डा० राजेन्द्र प्रसाद नेत्र विज्ञान केन्द्र
Dr. Rajendra Prasad Centre for Ophthalmic Sciences
A.I.I.M.S.
Ansari Nagar, New Delhi-110029



Section

Consultant Prof M S Bajaj

Sr. Resident Dr Sawani

Jr. Resident Dr Ashima

C.R. No		OPD No	
DR. RAJENDRA PRASAD CENTRE FOR OPHTHALMIC SCIENCES			
UHID:108313265	Date: 06/06/2025 10:42:54 AM		
CR No.:R-024207-25	Ward Name: RPC 1B	Bed No: 141	
Name: MR AMAN KUMAR	Unit In-charge: Dr. M. S. Bajaj		
Age 6 Y 11 M 28 D M	Unit-V		
S/O VIKRAM PRAJAPATI	ACCOUNTS-21-15898/202526 RS 140		
Address AT BARJO PO DHANWAR PS DHANWAR PIN 825412		JAMM JANT KASHMIR	

Sp. Clinic No.

Ward / Bed No.

~~151B~~
to Bed 141

Age

Sex

Nationality

en/d/6/25

Family Income

Single / Married

Permanent Address

(including self)

Occupation

D.O.A. Time


Local Address

D.O.D. Time

Previous Admission / CR No.

Admission-Routine / Emergency / EHS /

Tele No. 9708511758

DIAGNOSIS	Primary	2nd	3rd	Code No.
Right Eye VA - PL ⊕  IOP: Digitally ↑	R/E groupe E Retinoblastoma			1) No SI 2) 3)
Left Eye VA: 6/6 IOP: 12mm Hg	L/E fellow eye			1) 2) 3)

Medical / Operation Treatment


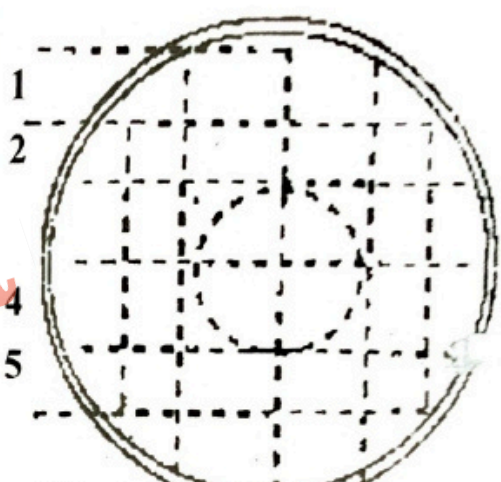
Result : Cured / Relieved / Stationary / Failure

Photographs No.

X-Ray No.

Histopath Report No.

wt=15 mg

	RIGHT	LEFT
<u>CORNEA</u>		
Size, Shape	normal size, shape	normal size, shape
Surface, Transparency	diffuse edematous	transparent
Ulcer	no ulcer	no ulcer
Vascularization	vascularisation +ve	no vascularisation
Opacity	@ limbus diffuse	no opacity
Degeneration	no opacity	no degeneration
Dystrophy	no degeneration	no dystrophy
Sensation	no dystrophy	A B C D E F
Thickness	F E D C B A	
		
<u>SCLERA</u>		
Shape, Vessels		
Nodules, Ectasia	no nodules, ectasia	no nodules, ectasia
<u>ANTERIOR CHAMBER</u>		
Depth	VH III	VH III
Regularity	no cells ⊕	no cells
Contents		no flare
Angle of A.C.		
<u>IRIS</u>		
Colour Pattern		Brown
Coloboma		NO neovascularisation
Nodules Vascularization	Ectropion uvulae ⊕	



SAVIOR FOUNDATION