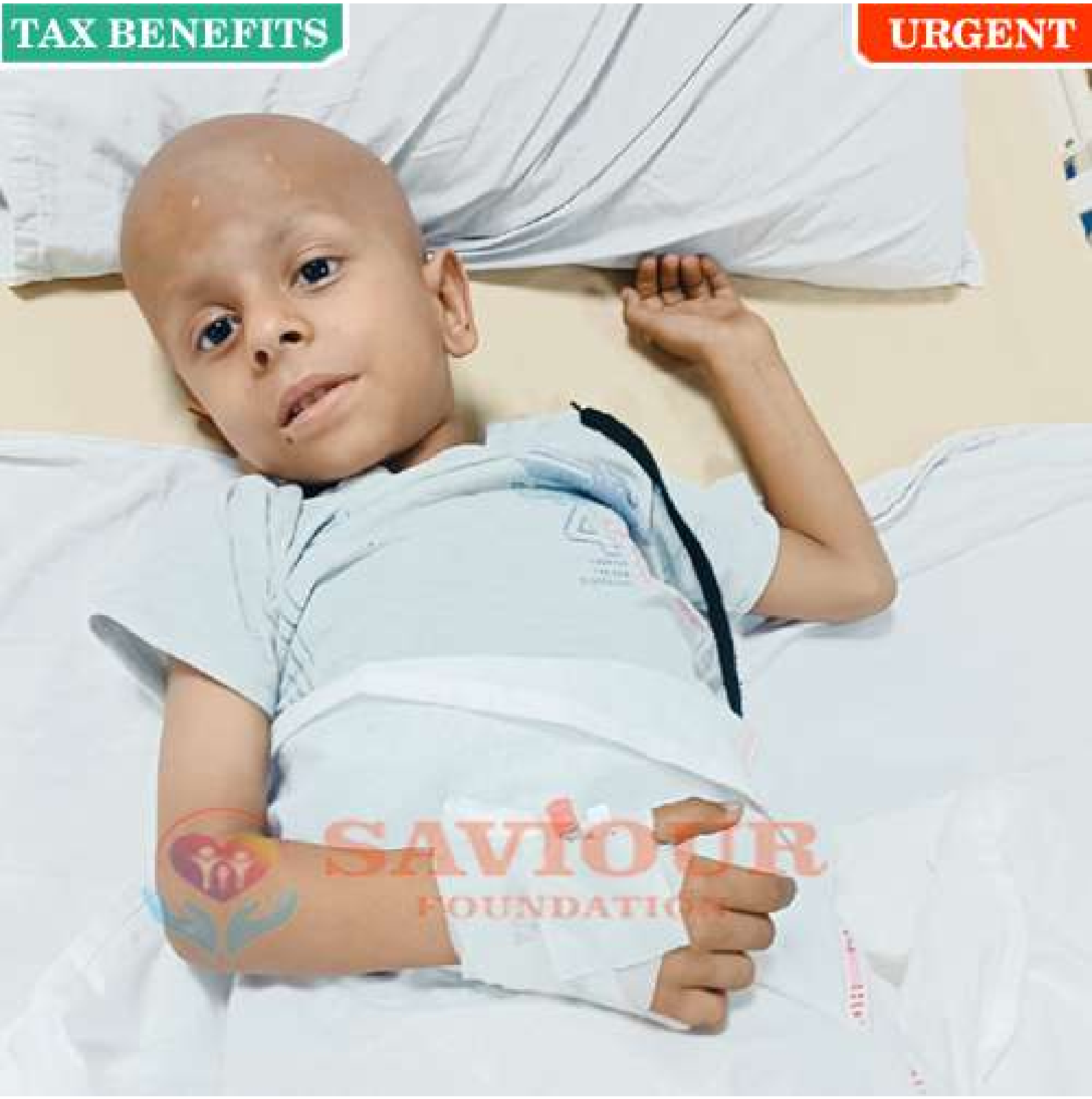

TAX BENEFITS

URGENT



Date: 08/10/24
 Doctor's orders with signature: [Signature]
 The sister's signature with date: [Signature]
 Name: Mr. Aryan Pandey
 Bed/Ward: 6A
 Age: 4.10 Y
 Sex: M
 Marital Status: Single
 UHID No. 107200072
 Religion: Hindu

ALL INDIA INSTITUTE OF MEDICAL SCIENCES, NEW DELHI-110029
 Bed/Room No. 66
 Unit B5
 DOA: 08/10/24
 DS's (H) High
 Rm 5

दिनांक / Date	08/10/24	09/10/24	10/10/24	11/10/24
समय / Time	12:30	1:30	2:30	3:30
ताप / Pulse ताप / Temp	100.4	100.5	100.5	102.2
Jy: Augmentin 160 41 105.5				
Jy: Gentamycin 140 40 104.0				
120 30 102.2				
100 38 100.4				
80 37 98.8				
60 34 98.8				
40 35 95.0				
Numerical Rating Scale Pain Scale				
Stool Urine Intake Output Weight Bath Special Drugs				

Sw - Excision of [unclear] muscle
 Rms with partial muscle
 excision of [unclear] muscle

← Pain / Pain Scale

IRCH No. 309987

Clinic Paediatric Medical Oncology Clinic

Deptt. MEDICAL ONCOLOGY

General

Reg. Date-04/04/2024

Clinic No. 2023/7082

IN HOSPITAL PREMISES

एकक/Unit
विभाग/Dept

नाम

Name AYAN PANDEY

S/O- anurag pandey

Phone No. [REDACTED]

Address C/O : Anurag Pandey keshav vihar dhanipur Aligarh Koil,
UTTRAKHAND, Pin.202001, INDIA



UHID-107200074

Sex/Age- M/4Y

Room 5 (Shift Afternoon)

सं/O.P.D. Regn. No.

आयु
Age

जन्म तिथि/Date of Birth

निदान/Diagnosis

दिनांक/Date

6/5/24

→ No opinion possible

RMS - Metastatic

उपचार/Treatment

Post Course 4 VAC

6.4 } 2900
N74 } 2.77L

Undocumented fever x 3 days

Coryza & headache (+)

No other complⁿ

Plan

Collect BM biopsy report - Teaching Block 1st floor R.No.1085

Bone scan

PRBC transfⁿ - Daycare (New pt. ward daycare)

Syp Cefpodoxime (100mg/sul) 5ml p/o BD x 5 days. ^{दोपहर}

RT OPD review - Registration d. Dr. Ahet ^(हिटर/957)
_{अहिर-5}

Peds Surgery OPD review

F/U 13/5/24 = CBC
Ht/Lt

-12-7-19

RE 1/2/3/INC/

MEDICAL
COLOGY
AIIMS

B+

7/5/24
7:30 AM



Dr. SHIVAM BANSAL
Senior Resident
Pediatric Oncology
AIIMS, New Delhi



Department of Nuclear Medicine and PET-CT
All India Institute of Medical Sciences
New Delhi, India

Patient Name: AYAN PANDEY		Age/Sex: 4Y/M
Study ID: MDP-49-20765-24	UHID: 107200074	Date: 15.05.2024

Indication: C/o Left thigh embryonal rhabdomyosarcoma- post chemo; Bone scan for metastatic spread.

^{99m}Tc – MDP WHOLE BODY BONE SCAN

Findings:

- *Physiological radiotracer activity noted in growth plates.*
- Normal radiotracer distribution noted throughout the skeleton.
- Bilateral kidneys are visualized.

IMPRESSION:

No definite scan evidence of osteoblastic cortical skeletal metastases in the present study.



प्रयोगशाला अर्बुद विज्ञान, डॉ भीमराव अम्बेडकर संस्थान रोटरी कैंसर अस्पताल
अखिल भारतीय आयुर्विज्ञान संस्थान नयी दिल्ली -110029
LABORATORY ONCOLOGY, Dr B.R.A. Institute Rotary Cancer Hospital All India Institute
of Medical Sciences, New Delhi-110029

UHID:	107200074	Reg Date :	18/12/2023 10:00 AM
Patient Name :	MR. Ayan Pandey	Age :	4 years 8 months 20 days
Sex :	Male	Unit Name :	Unit-I
Department :	Medical Oncology	Sample Collection Date:	13/05/2024 11:14 AM
Unit Incharge :		Lab Sub Centre:	Lab Oncology (IRCH)
Lab Name:	Lab Oncology	Report Generated Date:	15/05/2024 07:07 PM
Sample Received Date:	13/05/2024 02:54 PM	Recommended By:	Dr. SWASTHIK IRCH
Dept / IRCH No:	309987		
Lab Reference No:	1807		

Sample Details : LOI-130524068-BP (Bone Marrow)

BMA BMT PS

Report: Markedly diluted bone marrow preparation shows few scattered hematopoietic cells.
Peripheral smear shows leucopenia with adequate platelets.
Further opinion is not possible in this preparation.
Advice- Correlate with bone marrow biopsy
Senior resident: Dr Rani Sahu
Consultant: Dr G Smeeta

This is an electronically generated report, authorized signature is not required. The test reports have been authenticated.
Partial reproduction of the report is not permitted.

Authorized Signatory



प्रयोगशाला अबुर्द विज्ञान, डॉ भीमराव अम्बेडकर संस्थान रोटरी कैंसर अ
अखिल भारतीय आयुर्विज्ञान संस्थान नयी दिल्ली -110029
LABORATORY ONCOLOGY , Dr B.R.A. Institute Rotary Cancer Hospital All India
of Medical Sciences , New Delhi-110029

UHID:	107200074	Reg Date :	18/12/2023 10:00 AM
Patient Name :	MR. Ayan Pandey	Age :	4 years 8 months 5 d
Sex :	Male	Unit Name :	Unit-I
Department :	Medical Oncology	Sample Collection Date:	29/04/2024 11:32 AM
Unit Incharge :		Lab Sub Centre:	Lab Oncology (IRCH)
Lab Name:	Lab Oncology	Report Generated Date:	30/04/2024 05:13 PM
Sample Received Date:	29/04/2024 03:25 PM	Recommended By:	Dr. DEEPAK IRCH
Dept / IRCH No:	309987		
Lab Reference No:	1607		

Sample Details : LOI-290424077-TP (Bone Marrow)

BMT PS

Report: Bone marrow touch preparation is poorly prepared and show blood only.

Peripheral smear is unremarkable.

No opinion is possible in this marrow preparation.

Correlation with bone marrow biopsy.

Senior Resident : Dr Vanlalhruii

Consultant : Dr Amar Ranjan

This is an electronically generated report, authorized signature is not required. The test reports have been authenticated.
Partial reproduction of the report is not permitted.

Authorized Signator



Indoor Patient

Tab Dera 2mg OP after food x 3ay (फेब्रुअरी 3 दिने 24)

Tab Lam 2015 150 @ P. (फेब्रुअरी 24 दिने 24)

Syp 1002 200 (दोहरा 24)

Radiation oncology opinion - Dr. Ahith Bishnoi

FF on 7/03/2024 CC (IRFF) LFT
deepsu

16/2/24

To register Dr. A. Bishnoi on 12/3/24 room 3
8:30 am.

Bring all images & report on

[Signature]
Dr. A. Bishnoi

7/3/24

DAYCARE 1/2/3/NCI
MEDICAL ONCOLOGY
AIIMS
PRBC
Date: 8/3/24
Time: 7:30 AM

DAYCARE 1/2/3/NCI
MEDICAL ONCOLOGY
AIIMS
PRBC
Date: 11/3/24
Time: 7:30 AM

Adv:

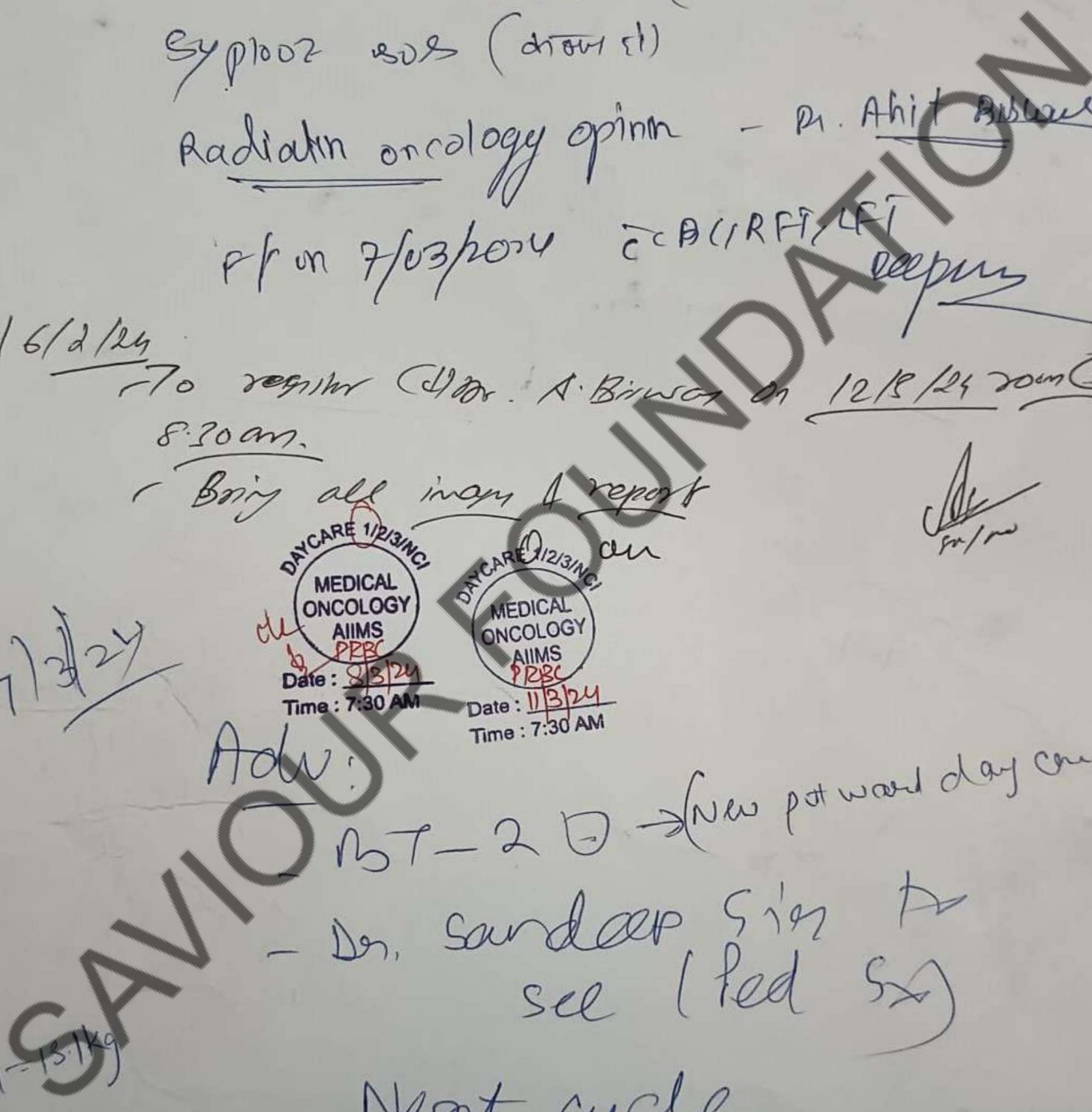
AST-2 D → (New pot ward day care)

- Dr. Sandeep Sien to see (Red 5x)

- Next cycle cycle dose to be ↓

- FF on 14/3/24 with CK

wt = 13.7kg



Firefox



Dr. R. P. ...

अखिल भारतीय आयुर्विज्ञान संस्थान, नई दिल्ली
MEDICAL SCIENCES, NEW DELHI

Reg. RMEE2115778

ISO CERTIFIED 9001 : 2015

Health Care Path Lab

(Fully Automated Computerised Lab)

Near Thana Gandhi Park, G.T. Road, Aligarh 202001

Mob.: 8791477578, 8958495846, 9520619747

E-mail: healthcarepathlab02@yahoo.com

Dr. R.K. Solanki

M.B.B.S (D.C.P.)

Mr. Lokesh Kumar

B.Sc., BMLT (Path)

Mr. M. Kumar

B.Sc. M.L.T. (Path)

Patient Name : Master Aryan Pandey Reg No. : 30
 Age/Sex : 4 Yrs. / MALE Date : 13/03/2024 5:19PM
 Referred By : Dr.SELF Reported On : 13/03/2024 5:22PM
 Sample By : Sample : BLOOD

REPORT	RESULTS	UNITS	REF.-RANGE
--------	---------	-------	------------

HAEMATOLOGY

COMPLETE BLOOD COUNT (CBC)

HAEMOGLOBIN	11.0	gm/dl	11.0-14.0
TOTAL LEUCOCYTE COUNT	4200	/cumm	5000-15000
DIFFERENTIAL LEUCOCYTE COUNT(DLC)			
Segmented Neutrophils	60	%	40-75
Lymphocytes	32	%	20-48
Eosinophils	06	%	00-06
Monocytes	02	%	00-03
Basophils	00	%	00-01
Immature Cells	00	%	

TOTAL R.B.C. COUNT	4.09	million/cumm	3.9-5.3
P.C.V./ Haematocrit value	35.1	%	30-42
M C V	85.82	fL	73-85
M C H	26.89	pg	24-30
M C H C	31.34	q/dl	31-37
PLATELET COUNT	2.39	lacs/mm ³	2.0-5.0
E.S.R (WINTROBE METHOD)			
-in First hour	22	mm	00-10

-----{End of Report}-----



डॉ. बी. आर. अम्बेडकर संस्थान रोटरी कैंसर अस्पताल
Dr. B.R. Ambedkar Institute Rotary Cancer Hospital
A.I.I.M.S. Hospital

OPR-6

DR. B.R.A. IRCH AIIMS, NEW DELHI
IRCH No. 309987 Reg. Date-18/01/2024
Clinic Paediatric Medical Oncology Clinic Clinic No. 2023/7082
Dept. MEDICAL ONCOLOGY General

Patient Department
PROHIBITED IN HOSPITAL PREMISES

नाम UHID-107200074
Name AYAN PANDEY
S/O- Anurag Pandey Sex/Age M/4Y
Phone No. Room 5 (Shift Afternoon)
Address C/O Anurag Pandey keshav vil ar dhanipur Aligarh Koti,
UTTARAKHAND, Pin 202001, INDIA

बनोविं पंजीकृत सं/O.P.D. Regn. No.

लिंग Sex	आयु Age	जन्म तिथि/Date of Birth

निदान/Diagnosis

① High ERMS Stage IV up IV

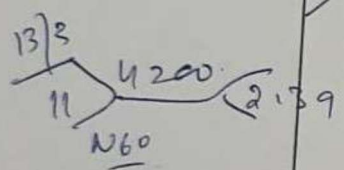
दिनांक/Date

14/3/24

उपचार/Treatment

(Fusion Station - NA)

Cause-3



- C. Apicap 80mg D₁-D₃ (C. treat given)
- Dy. Amisul 2mg
- Dy. Dera 2mg
- Dy. Pantar 25mg

(कम+15)

D1 CT
15/3/24

D2 CT
16/3/24

Dy. Vera 0.7mg slow IVP

14/3
21/3
28/3
15/3/24
22/3/24
29/3/24
D5/101

Dy. Actinomyun^o D 0.65 mg slow IVP - 14/3

Dy. Endoxan [380mg - D₁] IVP - 14/3
[300mg - D₂] IVP - 15/3

Dy. Mequa. 600mg IVP - D₁ - 14/3
D₂ - 15/3

Post CT

(कम 21-117)

Dy. GCSF 60 ug s/c OD - D5 onwards x 5 day

अंगदान-जीवन का बहुमूल्य उपहार / ORGAN DONATION - A GIFT OF LIFE

O.R.B.O. AIIMS, 26588360/26593444, www.orbo.org Helpline-1060 (24 hrs. service)

बाहर से आने वाले रोगियों के लिए सर्वप्रथम की...

19/3/24



अ० भी० आ० सं० अस्पताल / A.I.I.M.S. HOSPITAL
 बहिरंग रोगी विभाग / Out Patient Department



अस्पताल के अन्दर धूम्रपान करना है। / SMOKING IS PROHIBITED IN HOSPITAL PREMISES

डा. संदीप अग्रवाल
 Dr. Sandeep Agarwal
 Paed Surgery O.P.D.
 (रुक्कार) Friday

रुग्ण संज्ञांकन सं० / O.P.D. Regn. No.

सं० संस्था/उपस्था

UHID: 107200074

ABHA 0

Dept No.: 20240220001528

0-31

Unit

Paediatric Surgery OPD

Ayan Pandey

S/O Anurag Pandey

47, 6th 22D, M/GPRK

Add: D/O Anurag Pandey, Keshav Vihar, Dhanpur, Aligarh,
 Dist. UP, UTTARAKHAND, Pin-202001, INDIA

Mob: 9 [Redacted] New Patient, General 0

FR1

15/03/2024

Queue: N26



Registration: 10.23.24

वयु
Age

पता/Address

निदान/Diagnosis

④ Thick ERMS. on vac stage 4

दिनांक/Date

18

12 kg

उपचार/Treatment

from Med Oncol

Due for course 3 chrs

Appointment for Dept/Clinic

15/3/24

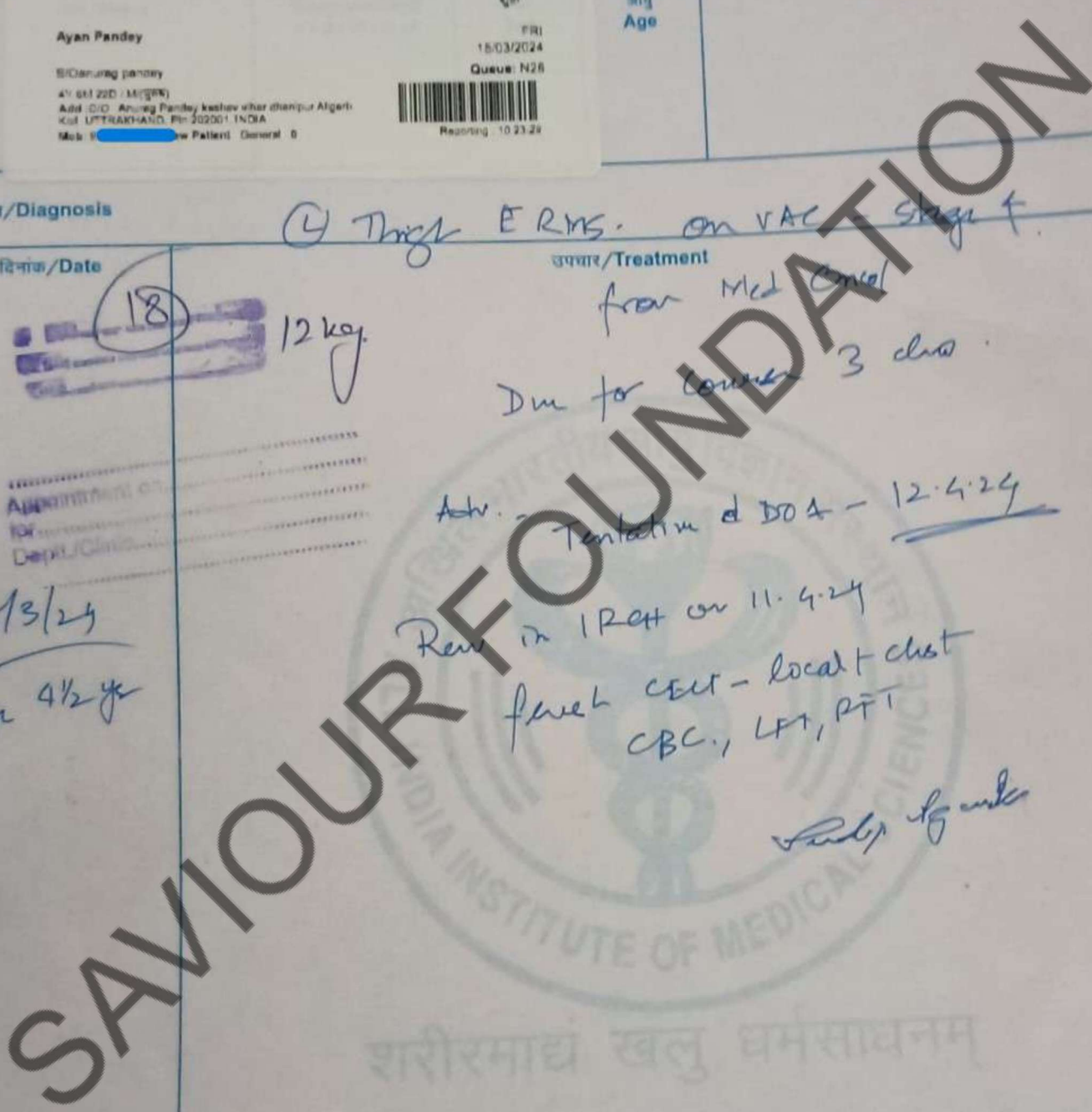
Age 4 1/2 yr

Adv. - Tentative d DOA - 12.4.24

Rev in IPatt on 11.4.24

fresh test - local + dist
 CBC, LFT, PFT

Sandeep Aggarwal



शरीरमाद्यं खलु धर्मसाधनम्



CLEAN AND GREEN AIIMS / एम्स का यही संकल्प, स्वच्छता से काया कल्प
 अंगदान-जीवन का बहुमूल्य उपहार / ORGAN DONATION - A GIFT OF LIFE
 O.R.B.O., AIIMS, 26588360, 26593444, www.orbo.org Helpline - 1060 (24 hrs service)



DR BR AMBEDKAR INSTITUTE ROTARY CANCER HOSPITAL, AIIMS, NEW DELHI-110029
DEPARTMENT OF RADIATION ONCOLOGY

DISCHARGE SUMMARY

REGISTRATION DETAILS

UHID No: 107200074 IRCH No: 309987
NAME: AYAN PANDEY AGE: 4 YRS GENDER: MALE
DOA: 12/1/24 DOD: 12/1/2024
WARD: PVT WARD BED No: 306
CONSULTANT INCHARGE: DR SAMEER BAKHSHI/DR DEEPAM PUSHPAM

DIAGNOSIS

DIAGNOSIS: MASS LEFT THIGH ? SPS

PROPOSE OF ADMISSION

USG GUIDED CORE BIOPSY

COURSE OF ADMISSION

PATIENT IS A C/O LEFT THIGH MASS UNDER EVALUATION. USG GUIDED BIOPSY WAS PERFORMED UNDER SEDATION. NOW PATIENT IS BEING DISCHARGED WITH STABLE VITALS.

ADVICE ON DISCHARGE

TAB PCM 125MG SOS

F/U IN OPD ¹⁸/1/24 WITH CBC/RFT/LFT/HPE REPORT

<https://ehospital.aiims.edu/ehospital/>

अखिल भारतीय आयुर्विज्ञान संस्थान, नई दिल्ली
ALL INDIA INSTITUTE OF MEDICAL SCIENCES, NEW DELHI
NATIONAL CANCER INSTITUTE

UHID:	107200074	Sex :	Male
Patient Name :	MR. Ayan Pandey	Sample Received Date :	01/01/2024 05:33 PM
Age :	4 years 4 months 8 days	Department :	Medical Oncology
Unit Name :	Unit-I	Unit Incharge :	
Lab Name:	NCI CORE LAB	Lab Sub Centre:	
Reg Date :	18/12/2023 10:00 AM	Sample Collection Date:	01/01/2024 01:21 PM
Report Generated Date:	02/01/2024 04:47 pm	Dept / IRCH No:	309987
Recommended By:	Dr. Amlesh Selhi	Lab Reference No:	3019

Sample Details : P010124053

Report

Test Name	Result	Comment	Normal Range
PROTHROMBIN (PT-INR)			
PT	12.80 sec		• 10.2 - 13.2 sec
INR	1.17		• < 1.1

Over All Comment :

Authorised Signatory

Verified
mahenpallab



ALL INDIA INSTITUTE OF MEDICAL SCIENCES, NEW DELHI
DEPARTMENT OF PATHOLOGY

Patient Name	: Ayan Pandey	UHID NO.	: 107200074
Accession No.	: S2418328	F/H Name	: NA
Age/Sex	: 4Y /Male	Additional ID	: N/A
Clinic/Dept.	: IRCH	Unit	: N/A
Consultant Incharge	: Dr. Sameer Bakhshi	Request Date/Time	: 29-04-2024 /11:32:51
		Receiving Date/Time	: 29-04-2024 /14:26:15

HISTOPATHOLOGY REPORT

GROSS EXAMINATION:

Accession No. : S2418328A

Specimen labelled as "Bone marrow biopsy" comprises of single linear bony cores measuring 0.6-0.8 × 0.2 × 0.2 cm.

MICROSCOPIC EXAMINATION:

Cor biopsy show fragment of skin, skeletal muscle and perichondrium. No marrow elements are seen.

Inadequate for opinion.

DIAGNOSIS:

S2418328A	Bone Marrow	Inadequate for opinion, see description above
-----------	-------------	---

End Report

Reporting Resident: Dr. Shiv Shankar Verma

Reporting Faculty: Dr. Lavleen Singh

Reporting Date/Time: 07-05-2024 13:00

Disclaimer :

This report is electronically generated and does not require a signature or stamp to be considered valid.

The pathology diagnosis is to be interpreted by the treating physician in conjunction with clinical features, imaging, and other investigations.



अखिल भारतीय आयुर्विज्ञान संस्थान, नई दिल्ली
 ALL INDIA INSTITUTE OF MEDICAL SCIENCES, NEW DELHI
 NATIONAL CANCER INSTITUTE

UHID:	107200074	Name:	MR. Ayan Pandey
Age :	4 years 7 months 10 days	Sex :	Male
Reg Date :		Verification Time:	03/04/2024 06:52 pm
Ward Name:		Lab Ref No:	1799
Unit Name :	Unit-I	Unit Incharge :	
Department :	PAED SURGERY	Sample Collection Date:	03/04/2024 01:25 pm
Lab Name:	NCI CORE LAB	Lab Sub Centre:	
Report Generated Date:	03/04/2024 06:57 pm	Dept / IRCH No:	20240220001528
Recommended By:	Dr. Minu Bajpai	Sample Recieved Date:	03/04/2024 05:18 PM

Sample Details : E030424534

Report

Test Name	Result	Comment	Normal Range
Hemoglobin	8.900 g/dL		• 13 - 17 g/dL 0Y - 100Y (M)
Hematocrit	28.6518 %		• 40 - 50 % 0Y - 100Y (M)
RBC Count	3.180 10 ¹⁵ /μL		• 4.5 - 5.5 10 ⁶ /μL 0Y - 100Y (M)
WBC Count	2.590 10 ⁹ /μL		• 4 - 10 10 ³ /μL 0Y - 100Y (A)
Platelet Count	287 10 ⁹ /μL		• 150 - 400 10 ³ /μL 0Y - 100Y (A)
MCV	89.100 fL		• 83 - 101 fL 0Y - 100Y (A)
MCH	27.8974 pg		• 27 - 32 pg 0Y - 100Y (A)
MCHC	31.0626 g/dL		• 31.5 - 34.5 g/dL 0Y - 100Y (A)
RDW	19.000 %		• 11.6 - 15 % 0Y - 100Y (A)
Neutrophils	69.100 %		• 40 - 80 % 0Y - 100Y (A)
Lymphocytes	15.000 %		• 20 - 40 % 0Y - 100Y (A)
Eosinophils	2.000 %		• 0 - 7 % 0Y - 100Y (A)
Monocytes	9.000 %		• 3 - 11 % 0Y - 100Y (A)
Basophils	0.400 %		• 0 - 2 % 0Y - 100Y (A)
Neutrophils - Abs	1.78969 10 ⁹ /μL		• 2 - 7 10 ³ /μL 0Y - 100Y (A)
Lymphocytes - Abs	0.3885 10 ⁹ /μL		• 1 - 3 10 ³ /μL 0Y - 100Y (A)
Eosinophils - Abs	0.0518 10 ⁹ /μL		• 0.02 - 0.5 10 ³ /μL 0Y - 100Y (A)
Monocytes - Abs	0.2331 10 ⁹ /μL		• 0.2 - 1 10 ³ /μL 0Y - 100Y (A)
Basophils-Abs	0.01036 10 ⁹ /μL		• 0 - 0.1 10 ³ /μL 0Y - 100Y (A)

Overall Comment :

Verified By

RADIOLOGY UNIT

Dr. B. R. Ambedkar Institute Rotary Cancer Hospital
All India Institute of Medical Sciences, New Delhi-110029

Patient Name: Mr.Ayan Pandey	Age/Gender: 4 Years and 4 Months / M
Patient UHID : 107200074	IRCH No : 309987
Accession No : 1351213	Location : MO OPD
Date of Examination : 04-JAN-2024 09:11 AM	

Procedure: **NCCT of Chest**

Clinical background: k/c/o STS

Mediastinum: Normal, No lymph node enlargement.

Trachea/ main bronchi: normal.

Both lungs: Normal; no focal lesion.

Serosal spaces: Normal. No pleural or pericardial effusion.

Comparison: None

Impression: Normal scan

Radiologist: Dr. Harpinder Singh (SR) / Dr. Sanjay Thulkar

