

Saviour foundation

RB-91/21

# ब० रो० वि० कार्ड O.P.D. Card



अनुभाग व दिन  
Section and Day **IV**

कमरा नंबर  
Cabin No.

डा० राजेन्द्र प्र  
अ० भा० आयु०  
Dr. Rajendra P  
A.I.I.M.S., New  
यू०एच०आई०डी०  
UHID No.

R.P. Centre (Exp. Centre)

UHID: 105753800  
Date: 27/12/2019

Dept. No.: 20210050086574  
RPC OPD Dr. SR/ F  
AMBIKA SARKAR SVF UNDER I-III IV R LAB  
D/O: JOYA

Unit: IV  
Room No.: 38B

Address: E-129 MET/ ASHOK NAGAR, DELHI-110049

रोगी का  
Name of the



*Handwritten signature*

दिनांक DATE	निदान DIAGNOSIS	उपचार Treatment
	(R) NV4. (L)	<p>no white opacity 95</p> <p>(R) X 2 R.H.</p> <p>O/E.</p> <p>(R) Frank NV2 (+)</p> <p>AC shallow (VH-1)</p> <p>(L) VH-2</p>

NCT < 59, 59  
19

VN < 6/24  
6/6

Pupil < Dilated  
No ocular  
Trauma.

(R) Delivered.

कृपया इस कार्ड को सुरक्षित रखें तथा अस्पताल में दिखाने के समय हर वक्त साथ लायें।

Kindly keep this Card safely and bring it on your follow-up visits.

- 1. धूम्रपान निषेध      2. कूड़ा कर्कट केवल कूड़ेदान में ही डालें      3. थूकिये नहीं
- 1. No Smoking              2. Use Dustbin              3. No Spitting

Investigations

Hb	ESR	TLC/DLC	B. Urea	S. Cr.	Na/K	Ca
B. Sugar F.	PP	R	T.P/A/G	OT/PT	TFT	
X-Ray Chest				ECG		
ECHO						
CT Brain				MRI		
Others						

Preanaesthetic Instructions:

Drug	Dose	Premedication Route	Time
------	------	---------------------	------

**Saviour foundation**

*[Signature]*  
Anaesthesiologist  
(Name)

7/1/22

Anaesthesia details: *Dr. [Signature]*

12:50 - 1 PM

I = O<sub>2</sub> + Sevo → AMBU #2-5

M = O<sub>2</sub> + N<sub>2</sub>O + Sevo

R =

ketop acetone

- Monitor vitals
- O<sub>2</sub> by FM @ 4L/min
- NPO till fully awake



ब० रो० वि० कार्ड  
O.P.D. Card



अनुभाग व दिन  
Section and Day **VI**  
बुधवार व शनिवार  
Wednesday & Saturday

कमरा नंबर  
Cabin No.

डा० राजेन्द्र प्रसाद नेत्र विज्ञान केन्द्र  
अ० भा० आयु० सं०, नई दिल्ली - 110029  
Dr. Rajendra Prasad Centre for Ophthalmic Sciences  
A.I.I.M.S., New Delhi-110029

यू.एच.आई.डी. संख्या  
UHID No. 105753800

आचार्य राधिका टंडन का एकक  
Prof. Radhika Tandon's Unit

रोगी का नाम Name of the Patient	पुत्र/पुत्री/पत्नी S/D/W	लिंग Sex	आयु Age	पता Address
Ambika Sankar				

दिनांक DATE	निदान DIAGNOSIS	उपचार Treatment
08/01/2022		<p>40/W Br surgery in NRC</p> <p>Mitroscopi eye notes</p> <p>LO noted</p> <p>dayc mass involving lens of</p> <p>retine</p> <p>After Ch not involved</p> <p>Not touching the lens</p>

RB clinic  
2:00pm  
142/43

कृपया इस कार्ड को सुरक्षित रखें तथा अस्पताल में दिखाने के समय हर वक्त साथ लायें।  
Kindly keep this Card safely and bring it on your follow-up visits.

- धूम्रपान निषेध 1. No Smoking
- कूड़ा कर्कट केवल कूड़ेदान में ही डालें 2. Use Dustbin
- थूकिये नहीं 3. No Spitting

दिनांक - Date

उपचार - Treatment

(R) mmms involving 170% of globe  
Mixed pattern RB.

Adw (RB) - 40 Mycin 725 5000 x 3 days

D/F Emulsion  
26/Jan  
~~OT 1st 1000/1000~~  
Ward PA 1800

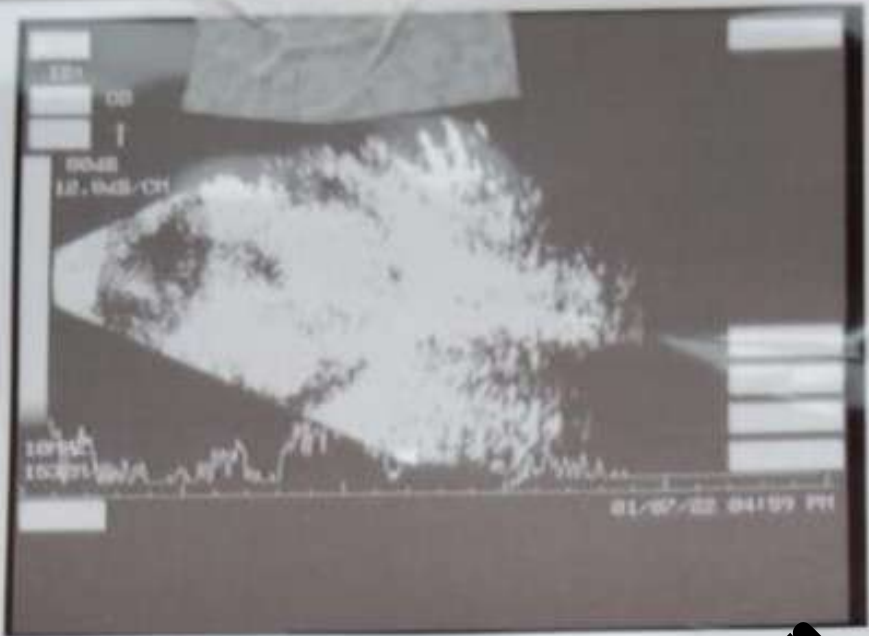
Mebr

नेत्र ईश्वरीय सर्वश्रेष्ठ उपहार है जिनका मनुष्य जीवन में दान करना परमश्रेष्ठ है।

इनकी पूर्ण रक्षा कीजिए ताकि ये आपकी रक्षा कर सकें।

Eyes are God's most precious gift to man kind and eye donation is the most noble deed.

Take full care of them so that they can take care of you.



अनुभाग व दिन  
 Section and Day VI  
 उपचार व शनिवार  
 Tuesday & Saturday

कमरा नंबर  
 Cabin No.

एकक  
 Unit

आयु  
 Age

पता  
 Address

(L) WNL.

**Saviour foundation**

उपचार Treatment

EUA done by Dr N. Lomi (Unit VI)

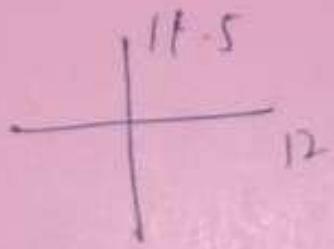
(R)

(L)

Echoplasm Ureter  
 NVI

WNL.

ED.



Pop

Immity

Immity

कृपया इस कार्ड को सुरक्षित रखें तथा अस्पताल में दिखाने के समय हर वक्त साथ लायें।  
 Kindly keep this Card safely and bring it on your follow-up visits.

- 1. धूम्रपान निषेध 2. कूड़ा कर्कट केवल कूड़ेदान में ही डालें 3. थूकिये नहीं
- 1. No Smoking 2. Use Dustbin 3. No Spitting



दिनांक - Date

उपहार - Treatment

(27) Department ush Nsb

u.  
03/18/2022

① Dr. Ho Jeeba  
mas e  
cele. f...  
5/0 1/13

Saviour foundation

Date  
Left Stopping

D/F EVA on 7/12/2022  
at 8AM OT 5th floor

card RTDUR - 5/01/22

NPO < GHN solid  
4hr liquid

03/18/2022

भैत्र ईश्वरीय सर्वश्रेष्ठ उपहार है जिनका मनुष्य जीवन में दान करना परमश्रेष्ठ है।  
इनकी पूर्ण रक्षा कीजिए ताकि ये आपकी रक्षा कर सकें।  
Eyes are God's most precious gift to man kind and eye donation is the most noble deed  
Take full care of them so that they can take care of you.

# EUA-CHART Anaesthesia Record

Dr. Rajendra Prasad Centre for Ophthalmic Sciences  
All India Institute of Medical Sciences, New Delhi-110029

Name Ambika Sarkar

Age/Sex 5y/f Ward/Bed SA

Ht/Wt 12kg

CR No. 10578 3500

ASA Grade (1) 2 3 4 5E

Diagnosis strabismic  
ES-VA ES-VA

Surgery

Ph. No.

**History & current drugs**

FT/NVD/CIAB NO H/O NCV strab / Development milestones achieved as per age

Immunised as per age

IV access good

NPO-6AM - Milk

Prematurity / post gestational age / cyanosis / ...

Previous Anaesthesia Exposure & its complications: None  
facile  
pediatric airway

**Congenital Anomalies / Syndrome:**

Airway examination: Mallampati Class

Teeth NLT

Neck movements: Retrognathia

High arched/cleft palate

Nasal Patency: Facies

Tongue

Tonsils: Intubation: simple / difficult

Respiratory System: Resp. Rate

Auscultation WFL NRS ⊕

Cardiovascular System: Heart rate

Pulse rate

Nack Veins

Precordial Thrill

Heart Sounds S<sub>1</sub> ⊕ S<sub>2</sub> ⊕ M<sup>o</sup>

Murmur

Preop. SpO<sub>2</sub>

IV access: inf.

Nervous System: MR / Delayed mile stones / CP / Seizures

**Musculoskeletal system examination**



दिनांक - Date

उपचार - Treatment

F<sub>1</sub> (R) Post glow

Adv

(27)

USG (R)

(R) VH/VF

(R) ... high spikes

Stop RB (E)

patient doesn't have camera  
PO not available

Ward IA

115

105

RB clinic Thursday

Review E  
MRI reports  
on Monday  
3/1/2022

for NRC  
discussion  
@ ward IA,  
9am

#7

CONTRAST enhanced  
but suppressed, axial, sagittal, coronal  
images optic nerve & pineal gland

नेत्र ईश्वरीय सर्वश्रेष्ठ उपहार है जिनका मनुष्य जीवन में दान करना परमश्रेष्ठ है  
इनकी पूर्ण रक्षा कीजिए ताकि ये आपकी रक्षा कर सकें।

Eyes are God's most precious gift to man kind and eye donation is the most noble deed.  
Take full care of them so that they can take care of you.



NAME:	BABY AMBIKA SARKAR	AGE/SEX:	05YRS/ FEMALE
REF. BY:	AIIMS	DATE:	01.01.2022 S NO - 102132116
INVESTIGATION:	MRI BRAIN AND ORBITS WITH CONTRAST		

**STUDY PROTOCOLS:**

MR IMAGING OF THE BRAIN WAS PERFORMED USING FLAIR, T1 AND T2 WEIGHTED AXIAL SECTIONS, AND CORRELATED WITH T2W SAGITTAL AND FLAIR CORONAL IMAGES. IMAGING OF ORBITAL REGIONS WAS PERFORMED USING CORONAL STIR, T1W AND T2W SECTIONS AND CORRELATED WITH T1W AND T2W AXIAL AND SAGITTAL IMAGES. POST CONTRAST IMAGES IN AXIAL, CORONAL AND SAGITTAL PLANES WERE ACQUIRED.

**Brain:**

Cerebral parenchyma appears normal in signal intensity with maintained grey and white matter differentiation. No focal parenchymal lesion or signal alteration is apparent, at present. No abnormal pineal mass lesion noted.

Diffusion weighted imaging carried out does not reveal any area revealing hyperintense signal intensity with increasing 'b' values.

Both cerebellar hemisphere and brainstem appear normal in morphology and signal intensity. Cerebellopontine angle regions appear normal.

Basal ganglia and thalamic regions appear normal in signal intensity.

Ventricles are normal in size and outline. Septum is in midline. Basal cisterns and sylvian fissures are normal.

Sellar and parasellar regions appear normal.

**Orbits:**

There is evidence of an intraocular mass lesion in right globe posteriorly, it is isointense on T1 & hypointense on T2, no definite areas of calcification noted. Post contrast study shows significant heterogeneous enhancement. It measures approx 1.9 (TR)x 1.1 (AP) cm. no definite evidence of any extra-ocular extension.

Left globe and bilateral extra ocular muscles appear normal. Retro-ocular space and fat planes are preserved.

Bilateral optic nerves grossly appear normal.

Optic chiasma appears normal in contours and signal intensity, at present.

Bilateral cavernous sinuses appear normal.

**IMPRESSION:** MR imaging reveals enhancing mass lesion in right globe posteriorly with extra-ocular extension – possibility of retinoblastoma (Advice: Further investigations)

DR SEEMA ALWADHI  
MD (Radio-Diagnosis)

Formerly SPECIALIST PGIMSR & ESI HOSPITAL (DELHI)

Disclaimer: The science of radiology is based upon interpretation of shadows of normal and abnormal tissue. This is neither complete accurate; hence, findings should always be interpreted in to the light of clinico-pathological correlation. This is a professional opinion, diagnosis. Not meant for medico legal purposes. Please intimate us for any typing mistakes and send the report for correction within 7 days.

Main Hub: B-35, Pusa Road, Opp. Metro Pillar No. 124, Delhi - 110005, Ph : 011-46243301/02/03

MRI 3.0 TESLA • SPIRAL CT SCAN • 4D COLOR DOPPLER/ULTRASOUND • DIGITAL X-RAY • ECG/EEG • ADVANCED PA

\* Clinical Correlation is essential for final diagnosis • If test result are unsatisfactory please contact personally • This report is only for perusal of doctor • Not for medico legal cases • All congenital anomalies in a fetus may not be diagnosed in routine obstetric ultrasound • Not included in NABL accreditation





Receipt No. 20210050086574

नगदी रसीद / CASH RECEIPT  
अखिल भारतीय आयुर्विज्ञान संस्थान / All India Institute of Medical Sciences  
अन्सारी नगर, नई दिल्ली-110029 / Ansari Nagar, New Delhi - 110029  
डॉ० राजेन्द्र प्रसाद नेत्र विज्ञान केन्द्र / Dr. Rajendra Prasad Centre for Ophthalmic Sciences  
दूरभाष / Phones : 2612, 26593115



Receipt No.:  
Received From:  
OPD/MRD No.:  
ON ACCOUNT OF

ACCOUNTS-21/64474/202122  
(Original)RPC Receipts  
MISS AMBIKA SARKAR ,Age :5 Yrs 0 Mons  
105753800 ( OPD )

27/12/2021  
Dated :  
Patient Type :  
Room No. :



Sl No.	Service Name	Quantity	Rate	Net Amount
1	INVESTIGATIVE LAB - US	1	25.00	25.00

Printed on 27 Dec 2021 12:50:02 PM

Cash  
25.0  
Rupees Twenty Five Only

MR.DINESH RPC

Payment Mode:  
INR (Rs.) :  
Rs. in Words





**GOVERNMENT DISTRICT COMBINED HOSPITAL, GAUTAM BUDDH NAGAR**  
**जिला संयुक्त चिकित्सालय, गौतमबुद्धनगर**



**Out Patient Department (OPD) Ticket**

Date: 2/1/20 Department: 15 OPD No. 132404  
 Patient Name: Lambika S / D / W/o \_\_\_\_\_ Age 5 Sex: M / F / Trans  
 Address: \_\_\_\_\_

Chief complaint(s):  
 History of present illness:  
 Past history / family history:  
 Medical / Surgical history / Known drug allergy:  
AE Cat's eye reflex  
fed to AI-IMS/GNES

General Physical Examination					
HI: _____ cm	Wt: _____ cm	Temp: _____ deg.F	Pulse: _____ /min	BP: _____ mmHg	RR: _____ /min
Pallor - Present / Absent		Icterus - Present / Absent	Oedema - Present / Absent	Cytopsis - Present / Absent	Dehydration - Mild / Mod / Severe

**Systemic Examination**

CNS: \_\_\_\_\_ CVS: \_\_\_\_\_ Resp: clear

**Local Examination**

Abdominal: \_\_\_\_\_ Chest: \_\_\_\_\_ Resp: \_\_\_\_\_

Differential diagnosis: \_\_\_\_\_ Treatment plan: \_\_\_\_\_  
 Investigations: \_\_\_\_\_ Rx: \_\_\_\_\_

**Saviour foundation**