

**SAVIOUR**<sup>®</sup>  
FOUNDATION  
REGD.NO.1937



**SAVIOUR**<sup>®</sup>  
FOUNDATION  
REGD.NO.1937



SAV

SA  
FO  
REG

ON

SAV

SAV  
FOUN  
REGD.

ATION

R

ATION

R





To

~~Dr. Loni~~

Dr. Loni / Dr. Bhawna ma'am

Kindly help us in knowing the response assessment

in this pt acc. to EVA-

He has already rec'd @ 8# HD (Eve) 2# Augmentin  
CT.

+ 4# IAC.

This will help us in deciding the further need of  
systemic chemotherapy.

Thank you  
Dr. Himanshu

29/11/23

C/D/W Dr. Loni

Respected ma'am,

The child went EVA & intravitreal  
Molipalolol was given yesterday (for active vitreous  
seeds). Assessment will be done after 3 weeks  
and need for IAC will be assessed. No need  
of systemic chemotherapy at present

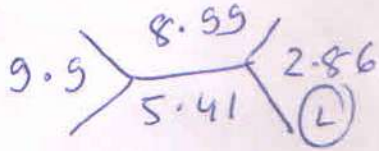
Thank you

Dr. Steepe

Dr. Steepe.

30/11/23

C/D/W Dr Lomi → No need of systemic chemotherapy at present.



LFT / KFT - (N)

→ R/V EUA after 3 weeks on 05/01/24

→ N/V on 06/01/2024.

SAVIOUR FOUNDATION

Menasee  
Dr. MANA  
Senior Registrar  
Pediatric Oncology  
Department of Pediatrics  
All India Institute of Medical Sciences  
New Delhi-110029



ब० रो० वि० कार्ड  
O.P.D. Card



नेत्र अमृत्यु रोगकार हैं  
जो आग ही से सकते हैं

अनुभाग व दिन  
Section and Day VI  
बुधवार व शनिवार  
Wednesday & Saturday

कमरा नंबर  
Cabin No.

420

डा० राजेन्द्र प्रसाद नेत्र विज्ञान केन्द्र  
अ० भा० आयु० सं०, नई दिल्ली - 110029

Dr. Rajendra Prasad Centre for Ophthalmic Sciences  
A.I.I.M.S., New Delhi-110029

यू०एच०आई०डी० संख्या  
UHID No.

105702612

आचार्य राधिका टंडन का एकक  
Prof. Radhika Tandon's Unit

रोगी का नाम Name of the Patient	पुत्र/पुत्री/पत्नी S/D/W	लिंग Sex	आयु Age	पता Address
Ajay Ahod		M	24 yrs	

दिनांक DATE	निदान DIAGNOSIS
7/11/23	S/P emulsified for Group ERB Group PRB

उपचार Treatment

NRC discussion

RE implant

PE mbeers indrs

CE USG can be done

- Ⓛ Tumour not discernible in mass the current film
- Ⓛ ON = not involved

Baseline MRI film needed for comparison  
and to comment upon progression/

Regression

कृपया इस कार्ड को सुरक्षित रखें तथा अस्पताल में दिखाने के समय हर वक्त साथ लायें।  
Kindly keep this Card safely and bring it on your follow-up visits.

1. धूम्रपान निषेध 1. No Smoking
2. कूड़ा कर्कट केवल कूड़ेदान में ही डालें 2. Use Dustbin
3. थूकिये नहीं 3. No Spitting

Ⓟ

दिनांक - Date

उपचार - Treatment

FU in old RBC 142B 2PM  
today

Mother wants to change  
Artificial eye  
dit ~~un~~ un ~~size~~ size

Ⓟ

GSB DR Comi sir

Plan Admit for

① EVA + VER

+ intracameral  
muphalan

Pt has  
next augmented  
chemo cycle  
due on 12/11/23

Ⓟ

Date - 15/11/2023

Ward No. 8m

25/11/2023

नेत्र ईश्वरीय सर्वश्रेष्ठ उपहार है जिनका मनुष्य जीवन में दान करना परमश्रेष्ठ है।  
इनकी पूर्ण रक्षा कीजिए ताकि ये आपकी रक्षा कर सकें।

Eyes are God's most precious gift to man kind and eye donation is the most noble deed.  
Take full care of them so that they can take care of you.





अ० भा० आ० सं० अस्पताल / A.I.I.M.S. HOSPITAL  
बहिरंग रोगी विभाग / Out Patient Department



अस्पताल के अन्दर धूम्रपान मना है। / SMOKING IS PROHIBITED IN HOSPITAL PREMISES

शरीरमार्चं खलु धर्मसाधनम्

OPR-6

बाल चिकित्सा विभाग.

कमरा / Room



UHID: 105702012  
ABHA: 0  
Dept No.: 20210030016033

C-217  
Unit-I

PCSC PAEDS

ब०रो०वि० पंजीकृत सं०/O.P.D. Regn. No. \_\_\_\_\_

AZRAF ABID

SIOSADIKUL ISLAM  
3Y 8M 1D / M(पुरुष)  
Add: Vill. Pa-Fahman Pather, ASSAM, Pin 782127, INDIA

30/11/2023

Queue: N7



Report no. 01-36-54

आयु  
Age

पता/Address

निदान/Diagnosis

दिनांक/Date

उपचार/Treatment

*(Handwritten mark)*

*13. Kg*

*N/v on 06/01/2024 c CBC / LFT / KFT*

*Manabe*

Dr. MANABE DEKA  
Senior Registrar  
Pediatric  
Department  
All India Institute of Medical Sciences  
New Delhi-110029

SAVIOUR FOUNDATION



CLEAN AND GREEN AIIMS / एम्स का यही संकल्प, स्वच्छता से काया कल्प  
अंगदान-जीवन का बहुमूल्य उपहार / ORGAN DONATION - A GIFT OF LIFE  
O.R.B.O., AIIMS, 26588360, 26593444, www.orbo.org Helpline - 1060 (24 hrs service)





**Dr. Rajendra Prasad Centre For Ophthalmic Sciences  
ALL INDIA INSTITUTE OF MEDICAL SCIENCES (AIIMS), New Delhi, 110029**

**Discharge Report  
PROVISIONAL DISCHARGE CERTIFICATE**

**UHID :** 105702612  
**Name:** Mr. AZRAF ABID  
**Age/Sex:** 3 years 5 mons 30 days / Male  
**Ward Name:** 4A  
**Address:** VIII\_Po-Falhamari Pather, ASSAM, Pin:782127, INDIA  
**Mobile No:** [REDACTED]  
**Date of Admission:** 25/11/2023 09:33:46 AM  
**Date of Discharge :** 28/11/2023 04:51:00 PM

**Cr No:** R-049302-23  
**Department:** R. P. Centre (Eye Centre)  
**Unit:** Unit-VI  
**Bed No.:** 420

**Drug Allergy,if any :-** [ ]

**ICD Code:** .C69.2  
**ICD Description:** Malignant neoplasm Retina

**Diagnosis**  
 .RE ANOPHTHALMIC SOCKET (S/P ENUCLEATION FOR GRP E RB)  
 LE GROUP D RB WITH RUBEOSIS IRIDIS

**Investigation**  
**Systemic** .NO SI  
**Ocular** RE- ENUCLEATED  
 LE  
 VA CARDIFF 6/60 AT 50 CM  
 IOP- DIGITALLY NORMAL  
 VER- 5.3 uv175 ms

**Treatment/Operative Procedure**  
**Surgeon** .DR N. LOMI / DR ANANYA  
**Date** 28/11/2023  
**Surgery** .EUA+INTRA VITREAL MELPHELAN UNDER GA UNDER GVP

**Condition at Discharge**  
**Anterior Seg.** .LE- FOLLOWS OBJECTS  
 DISCHARGE (+)  
 CONGESTION (+)  
 CONJUNCTIVA HEALTHY  
 CORNEA CLEAR  
 AC FORMED  
 LENS CLEAR  
**IOP** .LE- DIGITALLY NORMAL  
**Posterior Seg.** .LE GLOW PRESENT

**Advice During Discharge**  
**Oral** .SYP PCM 5 ML SOS FOR PAIN  
**Follow Up** AFTER 3 WEEKS FOR EUA IN #63 AT 8 AM ON .22/12/23  
 FRIDAY  
 NPO - 8 hrs solid, 6 hrs liquid  
 2 hrs - water  
**Topical** E/D MOXI- D QID  
 E/D REFRESH TEARS 6 T/D  
**Position** (V) 2 weeks → 2T/DX1W  
 8-12-4-8  
 6-9-12-3-6

RB/RCC inmed

GPM OS  
29/11/23



dense collection of seeds  
 changes of active seeds  
 UBm - No clo seeding in

atrophic patches on retina (old scars)  
 Total disc pallor

Easily PSC (+)



Peripheral out r Iris  
 synchial (+) mild atrophic iris  
 = fluffy membrane over iris  
 postv chamber.

Prepared By: Dr. PRITA KARMACHARYA  
 Signature Of Senior Resident

Date & Time  
 29/11/23

29/11/23

c/o. Sunday has broken eye  
R/E

Adm.

✓ ed. ceplon ③ x 1mk

✓ ed. cnc 0.5% ③

to continue

Removal once in  
2 months

↓  
adhere

SAVIOUR FOUNDATION



Case seen by SR Pediatrics

C10 Retino plastoma. / Planned for  
② eye enucleation

C10 running ASse x 1 day

C10 occasional cough x today after use.

No fever, No pain abdomen, No loose stools

No Breathing difficulty.

~~no~~ H10 travel

H10 cough hold in mother.

OE → active alert child

HR = 98/min

RR = 26/min

SpO<sub>2</sub> = 99% TPA

QFT < 3 sec

Peripheries → warm.

Pulses = w p

Risk of no retraction  
Auscultation → B/L A E ⊕, NRS no crepts, wheezes

R/A  
CNS  
CVS } IAD

Imp? - vital UP I.

Adv ✓ ① naso clear drops B/L nares q 6 hourly

② child can be taken up for surgery

Distrib

ward 4A RPC

- c/D/w Dr Vishakha

011 2659 3141

डॉ० राजेन्द्र प्रसाद नेत्र विज्ञान केंद्र - To be received

एम.आर.-9  
M.R.-9

Dr. Rajendra Prasad Centre for Ophthalmic Sciences

in MCB 4


विज्ञान संस्थान, नई दिल्ली-110029

ward at

Medical Sciences, New Delhi-110029

7pm

/ CONSULTATION RECORD

DR. RAJENDRA PRASAD CENTRE FOR OPHTHALMIC SCIENCES	
UHID:105702612	Date: 25/11/2023 09:33:46 AM
CR No.:R-049302-23	Ward Name: 4A Bed No: 420
Name: MR. AZRAF ABID	Unit In-charge: Dr. Radhika Tandon
Age: 3 Y 5 M 27 D/M	Unit-VI
S/O SADIKUL ISLAM	ACCOUNTS- RS. 21-57633/202324 140
Address Vill, Po-Falshaman Pather 782127 ASSAM	
	

लिंग	वैवाहिक स्थिति	के.पं.सं.
Sex	Marital Status	C.R. No.
बिस्तर	व्यवसाय	धर्म
Bed	Occupation	Religion
		स्थिति
		Status

Referred by Dr.

SR ophthalmology

Requesting Doctor

to Dr.

SR on call (Dr Vishakha Peds Consultant & Specialty man)

Findings :

Date :

Dear colleague.

On PAC  
pt has been  
advised for  
URI optimisation

My pt is 3yr / Male, Δsed as. (L) RB  
& planned for (L) enucleation + GA  
in the coming OT.

Diagnosis or Impression :

kindly review the pt & give your opinion regarding  
further mangement & optimisation of pt & clearance  
for sx

Recommendations:



Dr Manvi

Consultant's Signature





# ALL INDIA INSTITUTE OF MEDICAL SCIENCES

ANSARI NAGAR, NEW DELHI - 110029  
Telephone: 26588500, 26588700, 26589900  
Fax No.: +91-11-26588641, 26588663



## ~ ESTIMATE CERTIFICATE for financial assistance ~

DATE: .....

NAME: <u>Azraf Abid</u>	AGE: <u>02/M</u>	GENDER: <u>Male</u>
ADMISSION / TENTATIVE DATE:	UHID NO.: <u>105702612</u>	
DEPARTMENT: <u>Ophthalmology</u>	CONTACT NO. [REDACTED]	
AB-PMJAY (GOLDEN CARD): <u>P485X8IBX</u>	STATE: <u>Assam</u>	
ADDRESS:	PIN CODE: <u>782127</u>	

### PRE-PROCEDURE DETAILS FOR PRE-AUTHORISATION (To be filled by Treating Doctor)

Diagnosis: Retinoblastoma

Treatment Plan: left eye (L) IAC (triple regimen)

# Item-wise break-up of the estimate is as below:

Cost in Rs.

1. Injection OMNIPaque (LORERON 3mg-Sol)	1000 RS
2. Three way connector (BD) - 1	200 RS
3. ECG electrodes 6 Pieces	120 RS
4. Short connecting tubes with 3way - 2	100 RS
5. Long connecting tubes with 3way - 2	160 RS
6. Luer lock Syringes 10ml/10ml - 1	100 RS
7. Medicent 18G / Punctor Needle 18G - 1	50 RS
8. Exchange Sclerotic (Terna) 15mm 32 Angled	15000 RS
9. Double Luge Base Y-connector (Ment) - 1	100 RS
10. Femoral Sheath (arrow) SF x 7.5cm - 1	1000 RS
11. Eway SF - 1	- 11,300 RS
12. Marathon - 1	- 28,100 RS
13. Hybrid - 1	- 25,300 RS
14. Inj. melphalan 50mg/10ml - 2,500 RS	
15. Inj. Topotecan 2.5mg/2.5ml - 4,000 RS	
16. Inj. Carboplatin 150mg/15ml - 1,000 RS	
<b>TOTAL:</b>	<b>Rs: 76,430</b>

Dr. NEWETE LOMI  
Associate Professor  
Centre for Ophthalmic Research  
All India Institute of Medical Sciences, New Delhi

(Name & Signature of HOD with Stamp)